



# Risk Factors after Reduction to Single Antiplatelet Therapy for Postoperative Ischemia of Intracranial Stent-assisted Coil Embolization

Takafumi Mitsutake,<sup>1</sup> Yoshihisa Matsumoto,<sup>2</sup> Minoru Iko,<sup>1</sup> Masanori Tsutsumi,<sup>1</sup> Ayumu Eto,<sup>1</sup> Kouhei Nii,<sup>1</sup> Kimiya Sakamoto,<sup>1</sup> Kanae Kawahara,<sup>1</sup> Hiroshi Aikawa,<sup>1</sup> and Kiyoshi Kazekawa<sup>1</sup>

**Objective:** There are concerns regarding ischemic events associated with stent-assisted coil embolization. It is important to evaluate the risk factors for delayed thromboembolic events. This study evaluated risk factors after reduction to single-antiplatelet therapy 140–365 days after embolization.

**Methods:** We conducted a retrospective and cross-sectional study of patients who underwent stent-assisted coil embolization. Sixty eight aneurysms in 67 patients with unruptured intracranial aneurysms or the chronic phase of ruptured intracranial aneurysms between July 2010 and April 2014 were evaluated.

**Results:** Dual-antiplatelet therapy was administered for  $157 \pm 65$  days. Three patients who were administered the single-antiplatelet agent experienced postoperative ischemic events. One patient experienced cerebral infarction 143 days after the procedure. One patient with over 50% in-stent stenosis experienced cerebral infarction 194 days after the procedure. The final patient experienced transient ischemic attack (TIA) 223 days after the procedure, and re-embolization was performed 209 days after the procedure. Postoperative ischemic events occurred more frequently in severe in-stent stenosis patient ( $P < 0.05$ ).

**Conclusions:** However, severe in-stent stenosis may be a risk factor after reduction to single-antiplatelet therapy, relatively few ischemic events occurred after cessation of dual-antiplatelet therapy.

**Keywords** ▶ intracranial aneurysm, stent-assisted coil embolization, ischemic event, antiplatelet therapy

## Introduction

The utility of stent-assisted coil embolization for the endovascular treatment of intracranial aneurysms was reported for achieving high packing density,<sup>1)</sup> and management of coil deviation for aneurysms with a wide

neck.<sup>2,3)</sup> However, there are still concerns about patients experiencing a thromboembolic event after undergoing stent-assisted coil embolization.<sup>4-7)</sup> The optimal antiplatelet agent regimen has not yet been established.<sup>6,8)</sup>

The occurrence of a postoperative ischemic event is more likely to happen during the early stages after the procedure, and is associated with cessation of dual-antiplatelet therapy, which may reflect the important relationship with delayed thromboembolic complications after stent deployment.<sup>5,6, 8-10)</sup> Dual-antiplatelet therapy is usually used for 3 weeks to 6 months after the procedure, and single-antiplatelet agent is administered after discontinuation of dual-antiplatelet therapy.<sup>4-7)</sup> However, the increased likelihood of a hemorrhagic event caused by multiple antiplatelet agents should be mentioned.<sup>11,12)</sup> It is necessary to evaluate the risk factors for delayed thromboembolic events after reduction to single-antiplatelet therapy and to determine more suitable period of dual-antiplatelet therapy.

<sup>1</sup>Department of Neurosurgery, Fukuoka University Chikushi Hospital, Chikushino, Fukuoka, Japan

<sup>2</sup>Department of Neurosurgery, Tanushimaru Central Hospital, Kurume, Fukuoka, Japan

Received: March 17, 2017; Accepted: June 30, 2017

Corresponding author: Yoshihisa Matsumoto. Department of Neurosurgery, Tanushimaru Central Hospital, 892 Masuoda, Tanushimaru, Kurume, Fukuoka 839-1213, Japan  
Email: fwip4873@mb.infoweb.ne.jp



This work is licensed under a Creative Commons Attribution-NonCommercial-NoDerivatives International License.

©2017 The Japanese Society for Neuroendovascular Therapy

If the risk factors after reduction to single-antiplatelet therapy can be identified, then the timing necessary to reduce antiplatelet agents could be determined. We previously evaluated ischemic and bleeding events within 140 days after the procedure, and reported the utility of triple antiplatelet therapy for the first 6 weeks.<sup>13)</sup> Therefore, in the present study, we evaluated ischemic and bleeding events over the course of 140 days after the procedure.

## Materials and Methods

We conducted a retrospective, cross-sectional study from July 2010 to April 2014. The data from the medical information of patients who had unruptured intracranial aneurysms or the chronic phase ( $\geq 4$  weeks after aneurysmal rupture) of a ruptured intracranial aneurysm were collected. The study protocol was approved by the local ethics committee, and approval was obtained independently from each institution.

To evaluate the risk factors of single-antiplatelet therapy 140–365 days after stent-assisted coil embolization, we included patients for whom proposed antiplatelet therapy was maintained from the perioperative period to 365 days after the procedure. Triple- or dual-antiplatelet therapy was used prior to the procedure. Preoperative minimum doses were 200 mg aspirin, 300 mg clopidogrel, and 100 mg cilostazol. Maintenance doses were 81–100 mg/day aspirin, 75 mg/day clopidogrel, and 200 mg/day or 100–200 mg/day (during triple-antiplatelet therapy) cilostazol. After cessation of triple-antiplatelet therapy, dual-antiplatelet therapy was used.

Dual-antiplatelet therapy was maintained for at least 8 weeks after the procedure. Neurologic and radiologic evaluations, including MRI and DSA, were executed within several months after the procedure. After the follow-up evaluation, conversion from dual-antiplatelet therapy to single-antiplatelet therapy was performed. After cessation of dual-antiplatelet therapy, single-antiplatelet therapy was maintained over 365 days after the procedure. The timing of the follow-up evaluation, the selection of the antiplatelet drugs, and the duration of multiple antiplatelet therapies were left to the decision of the attending doctors.

Assessments by the neurologist or neurosurgeon 1 year after the procedure were required. If patients failed to comply, then they were excluded from the study.

Procedures were performed with general anesthesia, and heparin was administered before stent insertion. Final

angiography was performed after embolization at the working projection to evaluate the occlusion grade according to the Raymond grade<sup>14)</sup> and to detect any complications. To assess the risk factors for single-antiplatelet agent administration 140 days after embolization, ischemic and bleeding events were checked 140–365 days after the procedure.

## Definitions

The medical records depended on results of the patients' information and examinations. DSA, 3D DSA, MRI, and time-of-flight MRA for preoperative aneurysmal evaluations were performed and results were recorded. If the patient had stroke-like symptoms, then those symptoms were checked and imaging diagnosis was performed.

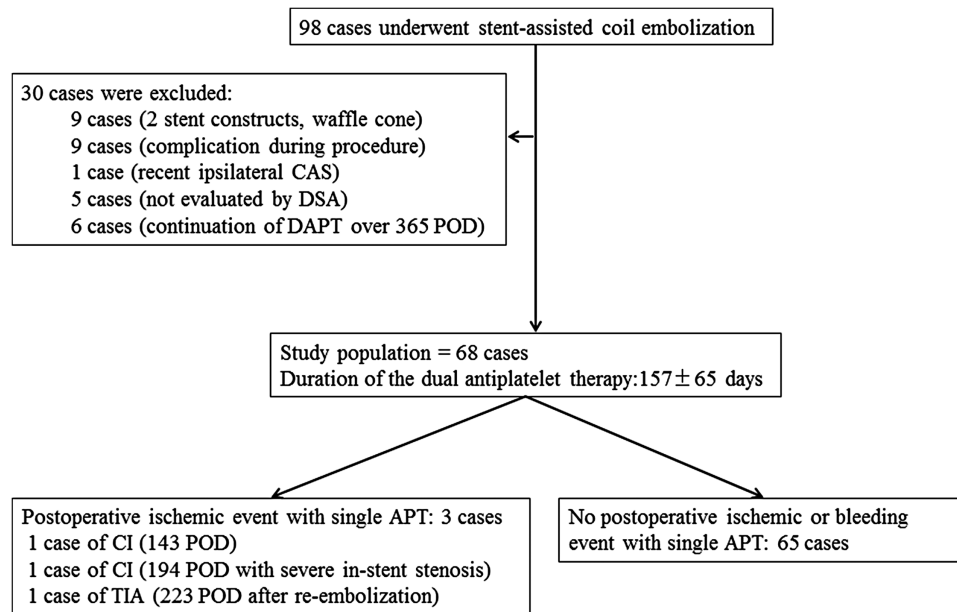
Cerebral infarction, transient ischemic attack (TIA), or symptoms of the eyes were determined for postoperative ischemic events. Cerebral infarction was defined if the patient experienced newly persistent neurologic dysfunction or if additional imaging abnormalities displayed cerebral infarction (i.e., additional high-intensity area detected by diffusion-weighted and T2-weighted MRI examination). TIA was determined if a temporary episode of neurologic deterioration occurred without new imaging abnormalities indicating cerebral infarction. If the patient experienced eye symptoms, then an ophthalmologist evaluated the patient. We defined a bleeding event if the patient experienced significant bleeding requiring blood transfusion, if intracranial bleeding was observed, or other important bleeding events as judged by each physician.

Target-lesion stenosis was determined using the Warfarin-Aspirin Symptomatic Intracranial Disease Study method in the follow-up DSA; the exact degree of stenosis was measured by comparing the diameter of the vessel at the site of stenosis (D stenosis) with the normal diameter of the vessel just distal to the stenosis (D distal) using the following formula:

$$\% \text{ stenosis} = (1 - [D \text{ stenosis}/D \text{ distal}]) \times 100\%.^{15)}$$

## Statistical analysis

The Mann–Whitney U-test was used for evaluation of significant differences in age, aneurysm size, and diameter of the parent artery. The Fisher's exact test was used for assessing all other parameters. Data are presented as the mean  $\pm$  standard deviation. Statistical significance was accepted if the probability level was less than 0.05.



**Fig. 1** Study flow chart. APT: antiplatelet therapy; CAS: carotid artery stenting; CI: cerebral infarction; DAPT: dual-antiplatelet therapy; POD: postoperative day; TIA: transient ischemic attack

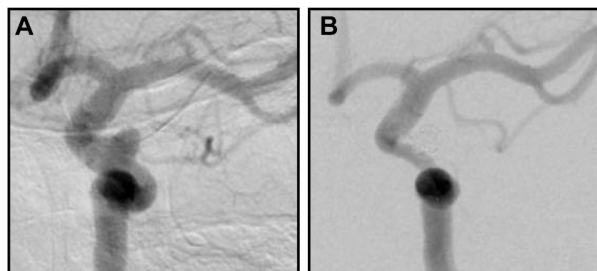
## Results

**Figure 1** shows the study flow. Of the 256 patients who had unruptured intracranial aneurysms or the chronic phase (>4 weeks after aneurysmal rupture) of a ruptured intracranial aneurysm during the 46 months, we excluded 146 patients who were not treated with a stent construct. Thirteen patients were not able to maintain the proposed antiplatelet therapy from the perioperative period to 365 days after the procedure.

We enrolled 97 patients (98 cases) who underwent stent-assisted coil embolization, and excluded 30 cases from the present study. Nine cases were treated by two stent constructs (coaxial and Y stent technique) or the waffle cone configuration. Nine cases experienced complications during the procedure (five cases experienced rupture of aneurysm or arterial perforation, two cases experienced coil migration to the parent artery that needed stent deployment emergently to fix the coil deviated out of the aneurysm and these patients experienced perioperative ischemic events, and two cases experienced dissection of the artery by catheter manipulation). One case experienced cervical carotid artery stenting at the ipsilateral side of the aneurysm within 3 months before coiling. We did not evaluate in-stent stenosis using DSA for five cases. Six cases were administered dual-antiplatelet therapy more than 365 days after the procedure.

Therefore, we evaluated 68 aneurysms in 67 patients (14 men and 53 women). The aneurysms were located in the internal carotid artery in 46 cases, the anterior communicating artery in seven, the middle cerebral artery in one, the vertebral-basilar artery in 12, the anterior cerebral artery in one, and the posterior cerebral artery in one case. The Enterprise VRD (Codman Neurovascular, Raynham, MA, USA) was deployed in 47 cases, and the Neuroform stent (Stryker Neurovascular, Fremont, CA, USA) was deployed in 21 cases. Thirty three cases were administered triple-antiplatelet therapy, and 35 cases were administered dual-antiplatelet therapy during the early postoperative period. Thirty one cases were switched from dual-antiplatelet therapy to monotherapy before 140 days after the procedure, and they did not experience postoperative ischemic events within 140 days after the procedure. Thirty seven cases were switched from dual-antiplatelet therapy to monotherapy within 140–365 days after the procedure. The dual-antiplatelet therapy was administered for  $157 \pm 65$  days (mean  $\pm$  standard deviation; median = 143 days; range, 58–342 days).

Between 140 and 365 days after the procedure, 3 of the 68 cases experienced ischemic events. They experienced motor weakness and/or sensory disturbance on the opposite side of the aneurysm and/or dysarthria and/or ataxia, which indicated the region of the vessel with stent deployment. These three cases were administered the



**Fig. 2** Angiography of an in-stent stenosis case. (A) DSA performed before the deployment of the coil and stent. (B) DSA performed 183 days after the procedure showed in-stent stenosis over 50%.

single-antiplatelet agent when the postoperative events occurred. We did not find evidence of arterial fibrillation or other cardiogenic embolic risk factors for these three cases. Before this study period, six cases experienced a postoperative ischemic event (two cases experienced mild cerebral infarction and four cases experienced TIA) within 140 days after the procedure; however, they did not experience postoperative ischemic events during this study period.

One case of cerebral infarction in the area of the stented vessel occurred 143 days after embolization of the vertebral-basilar artery aneurysm, 36 days after the antiplatelet agent was reduced from aspirin and clopidogrel to aspirin alone. Clopidogrel was reinstated after postoperative ischemic events, and the antiplatelet therapy was reduced again from aspirin and clopidogrel to only clopidogrel 342 days after the procedure, without additional ischemic events.

One patient experienced cerebral infarction 194 days after embolization of the internal carotid artery aneurysm. In-stent stenosis over 50% was defined as DSA 183 days after the procedure, and antiplatelet therapy was reduced from cilostazol and clopidogrel to cilostazol alone. Clopidogrel was reinstated after postoperative ischemic events occurred, but no additional ischemic event occurred (**Fig. 2**).

The other patient experienced TIA 223 days after embolization of the internal carotid artery aneurysm. Antiplatelet therapy was reduced from aspirin and clopidogrel to aspirin alone 185 days after the procedure. Because of coil compaction, re-embolization was performed 209 day after the procedure. Clopidogrel was reinstated after postoperative ischemic events, without additional ischemic events. All of the patients' symptoms were mild, and they were able to go home without assistance.

In-stent stenosis of 50% or more was found in one case on postoperative follow-up DSA. As mentioned above, this patient experienced cerebral infarction after reduction to

single-antiplatelet therapy. Incomplete occlusion (residual neck or sac) was found in nine cases. Re-embolization after stent implantation was performed in two cases. In one of the two re-embolization cases, re-embolization was performed with dual-antiplatelet therapy at 154 days after the procedure, and antiplatelet therapy was reduced from aspirin and cilostazol to aspirin alone 339 days after the procedure, without postoperative ischemic and bleeding events. As mentioned above, one patient experienced TIA.

Postoperative bleeding events and adverse events requiring termination of the antiplatelet agent did not occur during this study period.

We compared clinical information between patients who experienced postoperative ischemic events (three cases) and the other cases (65 cases). Postoperative ischemic events occurred more frequently in in-stent stenosis patients, and were statistically significant (Fisher's exact test;  $P = 0.04$ ). There were no statistically significant differences in other indices (**Table 1**).

## Discussion

The ischemic events after stent-assisted coil embolization were most likely to occur during the early period after embolization.<sup>16</sup> The rate of ischemic events was 3%–22%.<sup>5–7,9,10</sup> Delayed ischemic events were associated with cessation of dual-antiplatelet therapy.<sup>8,9</sup> However, life-threatening and major bleeding events occurred at a rate of 1.21%/year with single-antiplatelet therapy and 2.00%/year with dual-antiplatelet therapy.<sup>12</sup>

The anti-thrombotic property of stents could be associated with functional neointimal maturation. Animal experiments and angioscopic investigations of the coronary arteries regarding the neointima around the stent were reported.<sup>17,18</sup> The neointima was thickened up until 6 months after stenting for the coronary arteries and then thinned over a 3 year period.<sup>17</sup> Thrombus was observed more often during the early period and disappeared completely at 3 years.

This neointimal maturation may occur around the stent at the cerebral artery after intracranial aneurysm treatment. Neointimal remodeling was found histologically around the stent in the cerebral artery after intracranial aneurysm therapy.<sup>19</sup> Enterprise stent deployment causes in-stent stenosis 4–6 months after the procedure. This time-dependent phenomenon was completely resolved by 12–24 months after treatment.<sup>20</sup> In our study, a patient who experienced ischemic events 143 days after the procedure and

**Table 1** Statistical comparison of the group that experienced postoperative ischemic events and the one that did not

	Postoperative ischemic events (+)	Postoperative ischemic events (-)	P value
N	3	65	
Gender (men)	1	13	0.5
Age (y)	57 ± 14	60 ± 14	0.6
Hypertension	2	28	0.5
Diabetes mellitus	0	5	1
Dyslipidemia	1	18	1
Ischemic heart disease	0	4	1
History of cerebral infarction	0	3	1
History of subarachnoid hemorrhage	1	2	0.1
Re-embolization (past coiling before stent implantation)	1	4	0.2
Re-embolization (coiling after stent implantation)	1	1	0.08
Postoperative ischemic event within 140 POD	0	6	1
In-stent stenosis (>50%)	1	0	0.04*
Neck size of aneurysm (mm)	4.2 ± 1.0	4.9 ± 1.7	0.5
Dome size of aneurysm (mm)	5.0 ± 1.3	6.4 ± 2.8	0.3
Diameter of parent artery (mm)	3.1 ± 0.8	3.3 ± 0.8	0.6
Stent types			
Enterprise	2	45	
Neuroform	1	20	1
Antiplatelet therapy early postoperative period			
Triple	2	31	
Dual	1	34	0.6
Antiplatelet agent			
Aspirin	1	40	
Clopidogrel	1	17	
Cilostazol	1	8	0.3
Raymond score			
Complete occlusion	3	56	
Incomplete occlusion (residual neck or sac)	0	9	1

The Mann-Whitney U-test was used to determine significant differences in age, aneurysmal size, and diameter of the parent artery. Fisher's exact test was used for assessing all other parameters. \*P < 0.05 indicates statistical significance. POD: postoperative day

was reinstated with dual-antiplatelet therapy was shifted to single-antiplatelet therapy 342 days after the procedure without additional ischemic events.

The neointimal situation of severe in-stent stenosis may not have had adequate anti-thrombotic properties for single-antiplatelet therapy. Angiographic in-stent stenosis was seen in 3.4% (2.0% displayed 50% or greater in-stent stenosis) of patients in whom the Enterprise stent was used.<sup>10</sup> With the Neuroform stent, a 5.8% rate of moderate-to-severe (>50%) in-stent stenosis was found.<sup>21</sup> Spontaneous partial or complete resolution of severe in-stent stenosis was found after stent-assisted coil embolization.<sup>10,21,22</sup> If patients have no symptoms, then “watchful waiting” may be useful.<sup>21</sup> However, in-stent stenosis could be symptomatic, and some cases may require endovascular treatment or surgical bypass<sup>21</sup> and reinstatement of dual-antiplatelet therapy.<sup>23</sup> Chalouhi et al.<sup>22</sup> reported that patients with in-stent stenosis were continued or reinstated with dual-antiplatelet therapy and experienced no symptoms during follow-up.

The relationship between re-embolization after stent implantation and postoperative ischemic events was unknown. During this study, one patient experienced TIA

2 weeks after re-embolization with single-antiplatelet therapy. This event was considered a perioperative complication. Previously, incomplete occlusions were considered to be risk factors associated with delayed ischemic events after stent-assisted coil placement.<sup>9</sup> In our study, the incidence of postoperative ischemic events in incomplete occlusion cases was not statistically significant.

In this study, the average period of dual-antiplatelet therapy was 157 ± 65 days. We encountered three patients with an ischemic event with single-antiplatelet therapy during 140–365 days after the procedure. One postoperative ischemic event was considered a perioperative complication of re-embolization. One of these ischemic events was associated with severe in-stent stenosis. However, severe in-stent stenosis could be symptomatic and require continued or reinstated dual-antiplatelet therapy,<sup>21–23</sup> there were relatively few ischemic events during this study interval.

### Limitations

One of the limitations of the present study involved antiplatelet function. P2Y<sub>12</sub> reaction units and aspirin reaction units were not checked by monitoring systems such as the

VerifyNow Assay (Accumetrics, San Diego, CA, USA). This equipment could not be used at our institution during the study period. There have been reports indicating an 8%–45% incidence of aspirin resistance,<sup>24)</sup> and non-responders and low responders to clopidogrel comprised 28% of the volunteers.<sup>25)</sup> However, the statistically significant differences between each antiplatelet therapy was not defined in the present study, antiplatelet resistance should be considered.

This study involved a small number of cases. In addition, we excluded 30 cases because of the large variation of the study populations. Postoperative ischemia tended to occur in the early stage after the procedure;<sup>16)</sup> therefore, relatively few ischemic events occurred during the mid-term period. The statistical power of the study could have been insufficient and the antiplatelet agent regimen was not consistent. The decisions of each doctor may have been reflected in drug selection, and this selection bias could have affected the study results.

To overcome these limitations, a prospective and randomized trial with a larger number of patients is needed. Furthermore, more suitable antiplatelet administration for stent-assisted coil embolization and management for patients who experience perioperative complications need to be evaluated.

## Conclusion

However, severe in-stent stenosis may be a risk factor after reduction to single-antiplatelet therapy, there were relatively few ischemic events after cessation of dual-antiplatelet therapy administered  $157 \pm 65$  days after the procedure.

## Acknowledgment

We are grateful to Sumito Narita, Hidenori Yoshida, Taichiro Mizokami, Hosei Eto, Yu Iwae, Ritsuro Inoue, Yasuyuki Nomoto, Kousuke Kumagai, Hitoshi Maeda, Hayatsura Hanada, and Shuko Hamaguchi for their help with this study.

## Disclosure Statement

The first author and coauthors have no conflicts of interest.

## References

1) Bendok BR, Parkinson RJ, Hage ZA, et al: The effect of vascular reconstruction device-assisted coiling on packing

density, effective neck coverage, and angiographic outcome: an in vitro study. *Neurosurgery* 2007; 61: 835–840; discussion 840–841.

- 2) Henkes H, Bose A, Felber S, et al: Endovascular coil occlusion of intracranial aneurysms assisted by a novel self-expandable nitinol microstent (neuroform). *Interv Neuroradiol* 2002; 8: 107–119.
- 3) Sani S, Jobe KW, Lopes DK: Treatment of wide-necked cerebral aneurysms with the Neuroform2 Treo stent. A prospective 6-month study. *Neurosurg Focus* 2005; 18: E4.
- 4) Akpek S, Arat A, Morsi H, et al: Self-expandable stent-assisted coiling of wide-necked intracranial aneurysms: a single-center experience. *AJNR Am J Neuroradiol* 2005; 26: 1223–1231.
- 5) Kanaan H, Jankowitz B, Aleu A, et al: In-stent thrombosis and stenosis after neck-remodeling device-assisted coil embolization of intracranial aneurysms. *Neurosurgery* 2010; 67: 1523–1532; discussion 1532–1533.
- 6) Mocco J, Fargen KM, Albuquerque FC, et al: Delayed thrombosis or stenosis following enterprise-assisted stent-coiling: is it safe? Midterm results of the interstate collaboration of enterprise stent coiling. *Neurosurgery* 2011; 69: 908–913; discussion 913–914.
- 7) Mordasini P, Walser A, Gralla J, et al: Stent placement in the endovascular treatment of intracranial aneurysms. *Swiss Med Wkly* 2008; 138: 646–654.
- 8) Rossen JD, Chalouhi N, Wassef SN, et al: Incidence of cerebral ischemic events after discontinuation of clopidogrel in patients with intracranial aneurysms treated with stent-assisted techniques. *J Neurosurg* 2012; 117: 929–933.
- 9) Hwang G, Kim JG, Song KS, et al: Delayed ischemic stroke after stent-assisted coil placement in cerebral aneurysm: characteristics and optimal duration of preventative dual antiplatelet therapy. *Radiology* 2014; 273: 194–201.
- 10) Fargen KM, Hoh BL, Welch BG, et al: Long-term results of enterprise stent-assisted coiling of cerebral aneurysms. *Neurosurgery* 2012; 71: 239–244; discussion 244.
- 11) Diener HC, Bogousslavsky J, Brass LM, et al: Aspirin and clopidogrel compared with clopidogrel alone after recent ischaemic stroke or transient ischaemic attack in high-risk patients (MATCH): randomised, double-blind, placebo-controlled trial. *Lancet* 2004; 364: 331–337.
- 12) Toyoda K, Yasaka M, Iwade K, et al: Dual antithrombotic therapy increases severe bleeding events in patients with stroke and cardiovascular disease: a prospective, multi-center, observational study. *Stroke* 2008; 39: 1740–1745.
- 13) Matsumoto Y, Iko M, Tsutsumi M, et al: The safety and efficacy of triple antiplatelet therapy after intracranial stent-assisted coil embolization. *J Stroke Cerebrovasc Dis* 2015; 24: 1513–1519.
- 14) Roy D, Milot G, Raymond J: Endovascular treatment of unruptured aneurysms. *Stroke* 2001; 32: 1998–2004.

- 15) Chimowitz MI, Kokkinos J, Strong J, et al: The warfarin-aspirin symptomatic intracranial disease study. *Neurology* 1995; 45: 1488–1493.
- 16) Matsumoto Y, Nakai K, Tsutsumi M, et al: Onset time of ischemic events and antiplatelet therapy after intracranial stent-assisted coil embolization. *J Stroke Cerebrovasc Dis* 2014; 23: 771–777.
- 17) Asakura M, Ueda Y, Nanto S, et al: Remodeling of in-stent neointima, which became thinner and transparent over 3 years: serial angiographic and angioscopic follow-up. *Circulation* 1998; 97: 2003–2006.
- 18) Schatz RA, Palmaz JC, Tio FO, et al: Balloon-expandable intracoronary stents in the adult dog. *Circulation* 1987; 76: 450–457.
- 19) Lopes D, Sani S: Histological postmortem study of an internal carotid artery aneurysm treated with the neuroform stent. *Neurosurgery* 2005; 56: E416; discussion E416.
- 20) Gao B, Safain MG, Malek AM: Enterprise stenting for intracranial aneurysm treatment induces dynamic and reversible age-dependent stenosis in cerebral arteries. *J Neurointerv Surg* 2015; 7: 297–302.
- 21) Fiorella D, Albuquerque FC, Woo H, et al: Neuroform in-stent stenosis: incidence, natural history, and treatment strategies. *Neurosurgery* 2006; 59: 34–42; discussion 34–42.
- 22) Chalouhi N, Drueding R, Starke RM, et al: In-stent stenosis after stent-assisted coiling: incidence, predictors and clinical outcomes of 435 cases. *Neurosurgery* 2013; 72: 390–396.
- 23) Fiorella D, Albuquerque FC, Woo H, et al: Neuroform stent assisted aneurysm treatment: evolving treatment strategies, complications and results of long term follow-up. *J Neurointerv Surg* 2010; 2: 16–22.
- 24) Macchi L, Sorel N, Christiaens L: Aspirin resistance: definitions, mechanisms, prevalence, and clinical significance. *Curr Pharm Des* 2006; 12: 251–258.
- 25) Lau WC, Gurbel PA, Watkins PB, et al: Contribution of hepatic cytochrome P450 3A4 metabolic activity to the phenomenon of clopidogrel resistance. *Circulation* 2004; 109: 166–171.