福岡大医紀（*Med. Bull. Fukuoka Univ.*）：39(1)，1–3，2012

Treatment of Lentigo Seniles Using a Q-switched Ruby Laser

Noriko SATO, Juichiro NAKAYAMA

Department of Dermatology, Faculty of Medicine, Fukuoka University

Abstract：This report presents three cases of lentigo seniles that were recently treated using a Q-switched ruby laser, with a discussion of the therapeutic outcomes and future prospects. The three cases included lentigo seniles with a good clinical course, male lentigo seniles with periocular keratosis and lentigo seniles with telangiectasia. Lentigo seniles with a clear boundary and without inflammation is unlikely to produce pigmentation after laser treatment. The treatment prevented the loss of eyelashes in the second case and the patient's eyeballs were protected throughout the therapy. Lentigo seniles with telangiectasia was treated using double lasers（Q-switched ruby laser and flash lamp excited pulsed dye laser）. Full understanding of lentigo seniles will allow these laser treatments and safe irradiation to yield a good clinical course.

Key words：**Lentigo seniles, Good responder, Periocular lesion, Telangiectasia, Q-switched ruby laser, Flash lamp excited pulsed dye laser**

Introduction

Improvements in laser technology have led to novel treatment method for skin diseases that yield good cosmetic results. However, treatment of lentigo seniles on the face is difficult because there is often post-laser repigmentation. In addition, treatment of the area around the eyes requires extreme caution.

Subjects and Methods

1）Lentigo seniles with a good clinical course（**Fig. 1**）

A 55-year-old female developed pigmented macules in the lower jaw several years earlier. A Q-switched ruby laser（694 nm, 20 ns, NIIC Company, 4.5 J/cm^2, 4 shots）was applied once. The crusts dropped one week later, and the patient remained recurrence-free for more than 1 year without pigmentation.

2）Male lentigo seniles（**Fig. 2**）

A 59-year-old male presented with 3 cm solar lentigo in the medial part of the left eyelid. Liquid nitrogen therapy was risky because liquid nitrogen oozing from the pledget could damage the eyeball. Therefore, a Q-switched ruby laser（694 nm, 20 ns, JMEC Company, 4.5 J/cm^2, 38 shots）was selected for treatment. The eyeball was protected using a contact-type eye shield during periocular laser application. The lid margin was irradiated with a dose that did not cause a loss of eyelashes. His skin rash became scabbed after one application and then nearly disappeared. There was only reddish pigmentation for 4 months in a 1 cm portion below the left eyebrow. The condition was differentially diagnosed as solar keratosis, but a biopsy revealed nothing more than pigmentation.

3）Lentigo seniles with telangiectasia（**Fig. 3**）

A 65-year-old female presented with a 3 cm brown lentigo seniles on the right cheek. Although she had previously undergone several courses of liquid nitrogen therapy, her skin lesion remained unchanged. Telangiectasia was present above and under the lentigo seniles. A Q-switched ruby laser（694 nm, 20 ns, JMEC Company, 6 J/cm^2, 21 shots）was applied. The lentigo seniles dropped, with no pigmentation. The remaining areas of telangiectasia were irradiated with a flash lamp excited pulsed dye laser（V-beam perfecta, 595 nm ±

Correspondence to：Noriko SATO Department of Dermatology, Faculty of Medicine, Fukuoka University
7-45-1, Jonan-ku, Fukuoka, 814-0180, Japan
TEL. 092-801-1011 FAX 092-861-7054 Email： satonori@fukuoka-u.ac.jp

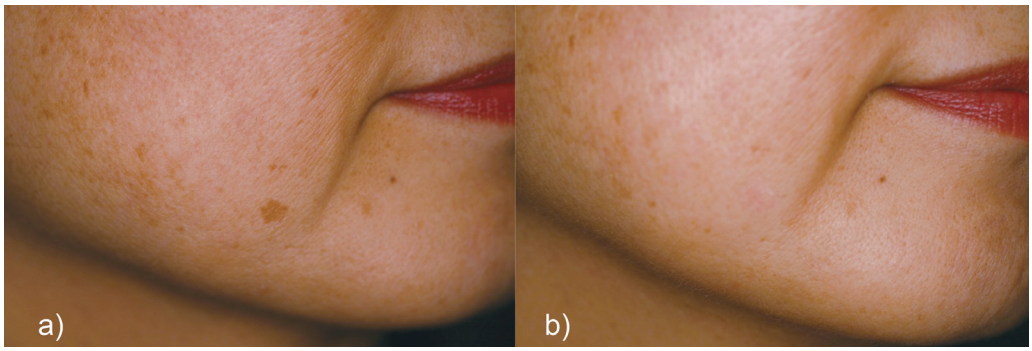

Fig. 1. a) Pretreatment with the Q-switched ruby laser
b) Post treatment with the Q-switched ruby laser seven days

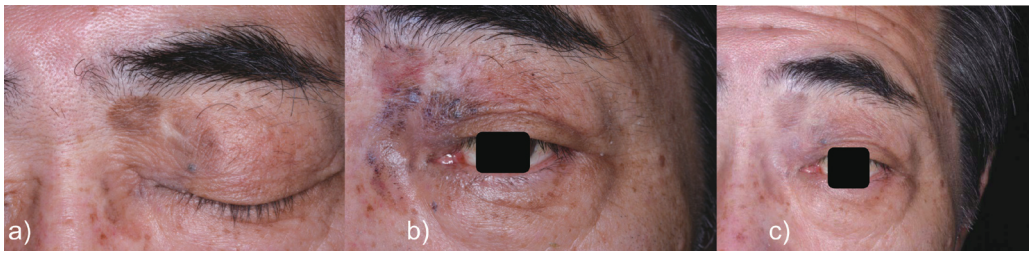

Fig. 2. a) Pretreatment with the Q-switched ruby laser
b) Post treatment with the Q-switched ruby laser after eight days
c) Post treatment with the Q-switched ruby laser after forty-two days

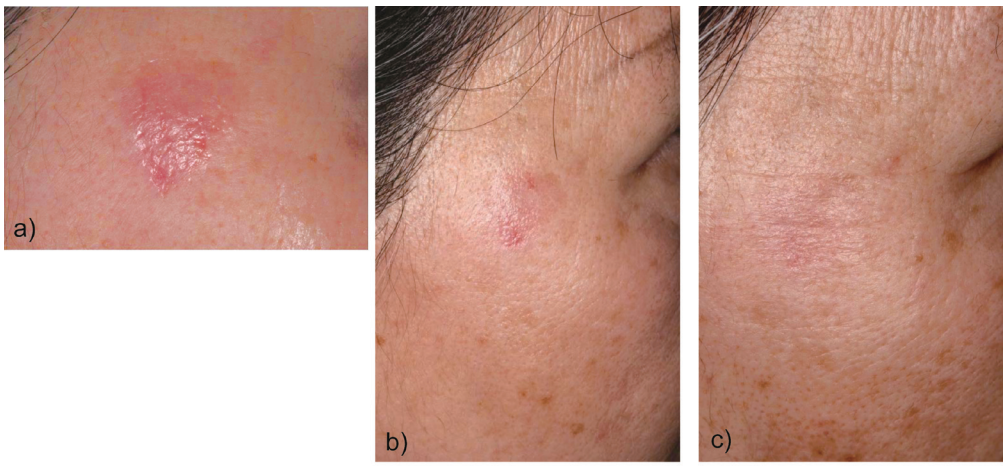

Fig. 3. a) Pretreatment with the Q-switched ruby laser
b) Post treatment with the Q-switched ruby laser after two months + pretreatment with the flash lamp excited pulsed dye laser
c) Post treatment with the Q-switched ruby laser after two months + post treatment with the flash lamp excited pulsed dye laser after seven days

5 nm, Candela Company, Fl 7 J/cm^2, diameter 10 mm, duration 10 ns, DCD 40/20, 2 shots) two months later. All of the lesions had disappeared one week later, with no purpura formation.

Discussion

Lentigo seniles is a type of age spot that develops in light-exposed surfaces of the skin in individuals over 50 years of age. The Q-switched ruby laser was developed initially for the removal of tattoos and congenital pigmented lesions such as nevus of Ota. The Q-switched ruby laser is used to treat pigmented lesions, since it is unlikely to be absorbed by hemoglobin because of its wavelength of 694 nm, and the application time is shorter than the thermal relaxation time of 50 nanoseconds for melanosomes[1].

The whitening phenomenon is used to guide the point of application of the post laser irradiation for effectively destroying lentigo seniles and preventing pigmentation[2]. Lentigo seniles with a clear boundary and without inflammation like that in case 1 is unlikely to produce pigmentation after laser treatment. Lentigo seniles with surrounding inflammation is known as lichen planus like keratosis (LPLK). LPLK responses to laser treatment are variable, and inflammation and pigmentation are often prolonged following treatment.

Lentigo seniles has various profiles, including proliferating keratinocytes and stimulating melanocytes. The endothelins synthesized in stimulated endothelial cells activate melanocyte function[3]. The reason to Q-switched ruby laser treatment may be due to destruction of the proliferating keratinocyte and limited stimulation of the surrounding melanocytes.

Case 2 was lentigo seniles with periocular keratosis. The differential diagnosis was actinic keratosis. Although there was slight erythema, there was no evidence of vascular dilation and the surface had a uniform texture; thus the disease was diagnosed as lentigo seniles. Histopathological examination of the pigmented portions after 4 months revealed the absence of epidermal cell atypia, confirming the diagnosis of lentigo seniles. While emphasis should be placed on the prevention of the loss of eyelashes and the protection of the eyeballs, the treatment of periocular lesions is highly effective in restoring a youthful facial appearance, provided that no side reactions occur.

Case 3 had solar lentigo with telangiectasia that was treated using a Q-switched ruby laser followed by application of a flash lamp excited pulsed dye laser two months later. V-beam perfecta (flash lamp excited pulsed dye laser) are applied to vascular lesions. The treatment was a type of sequential therapy. The combined use of lasers with different wavelengths has an increased therapeutic effect leading to higher patient satisfaction.

A wareness surveys of female patients at the outpatient clinic of the department of aesthetic dermatology show most visit the clinic since they want to have medical treatment for their own benefit. Male patients usually seek treatment to improve their social status.

Therefore, the Department of aesthetic dermatology is expected to find a growing therapeutic demand in the future.

Hopefully, physicians and other staff will develop increased expertise for accurate diagnosis, and application of the equipment. This should therefore positively contribute to improving the quality of life for people in the aging society through better practice at aesthetic medical centers.

References

1) Anderson RR, Parrish JA. Selective photothermolysis: precise microsurgery by selective absorption of pulsed radiation. Science 29: 524-527,1983
2) Hruza GJ, Dover JS, Flotte TJ, Goetschkes M, Watanabe S, Anderson RR. Q-switched ruby laser irradiation of normal human skin. Arch Dermatol 127: 1799-1805,1991
3) Kadono S, Manaka I, Kawashima M, Kobayashi T, Imokawa G. The role of the epidermal endothelin cascade in the hyperpigmentation mechanism of lentigo seniles. J Invest dermatol 116: 571-577,2001

(平成 23. 8. 22 受付, 平成 23. 11. 30 受理)